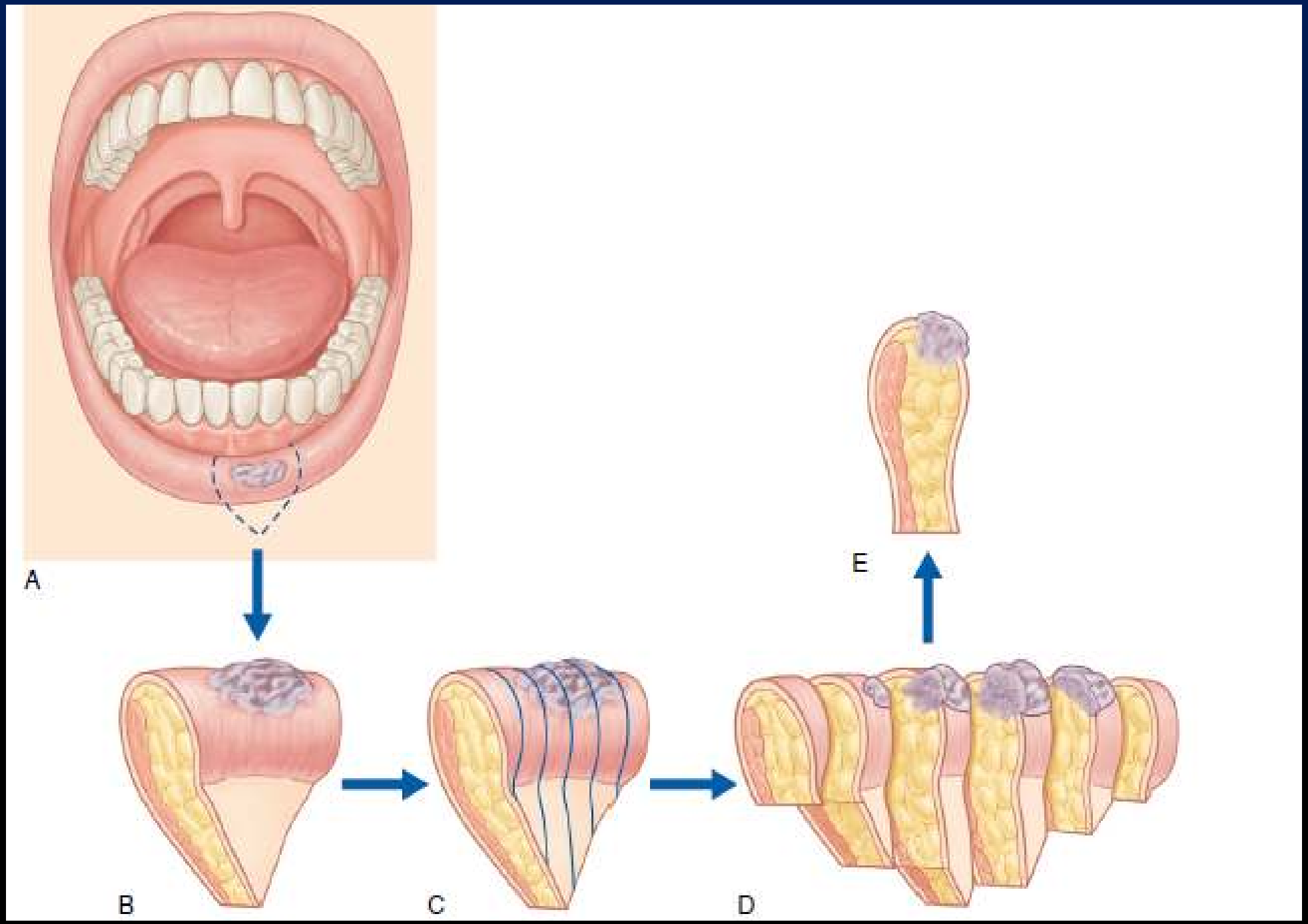
A
B
C
D
E

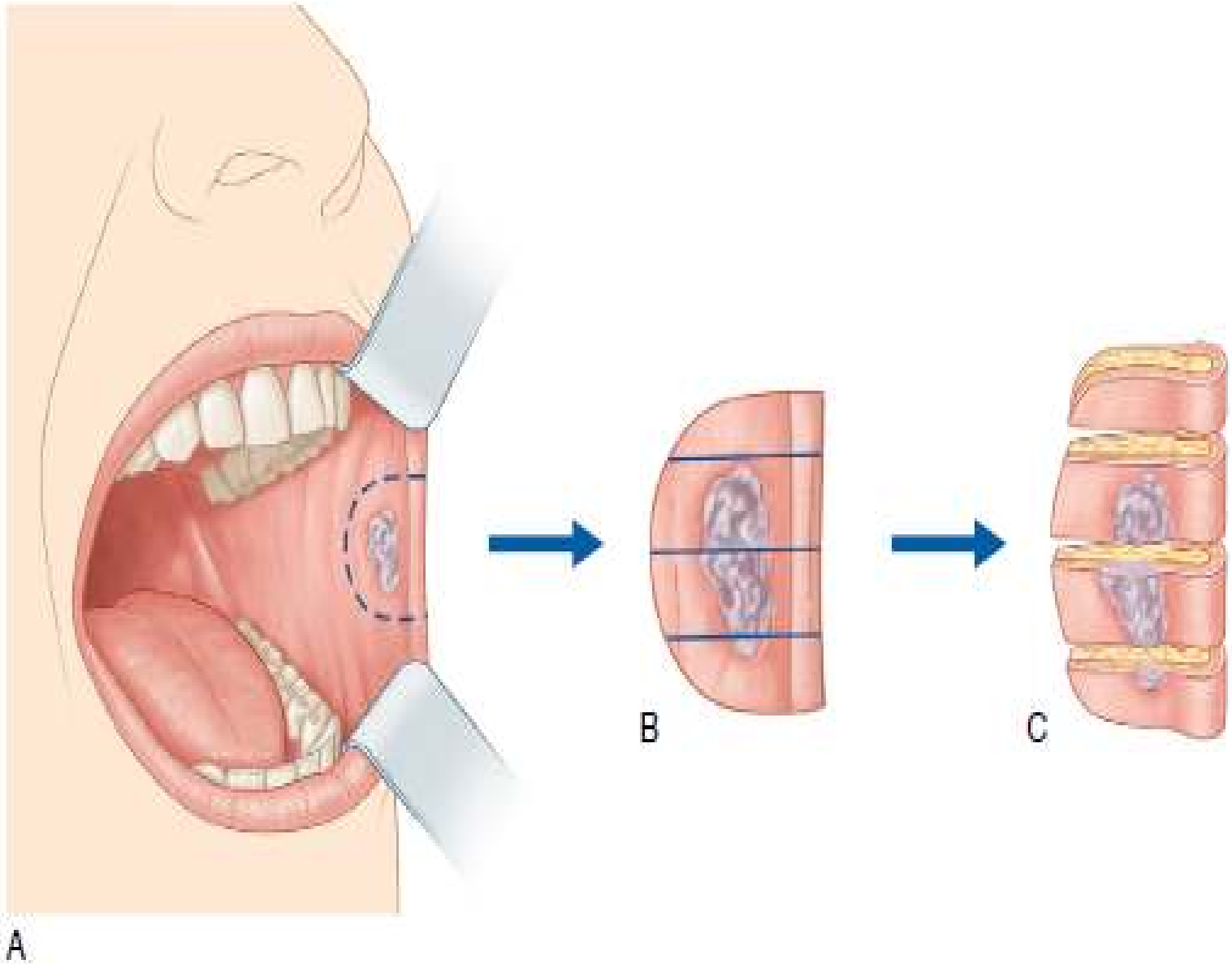
A
B
C


247/012
ماعة مير
د. وليد غليل

facial Histopathology Department of Oral Diagnosis
port

253/92 رفع الاجزاء

Referred by Surgeon: د. سندس انور محمد

Hospital: المركز الصحي اسنان الكرامة

Date & Signature: د. فولة تسعة
٤ ١٠/١٩

cal history: No Sign & symptom of any systemic dis

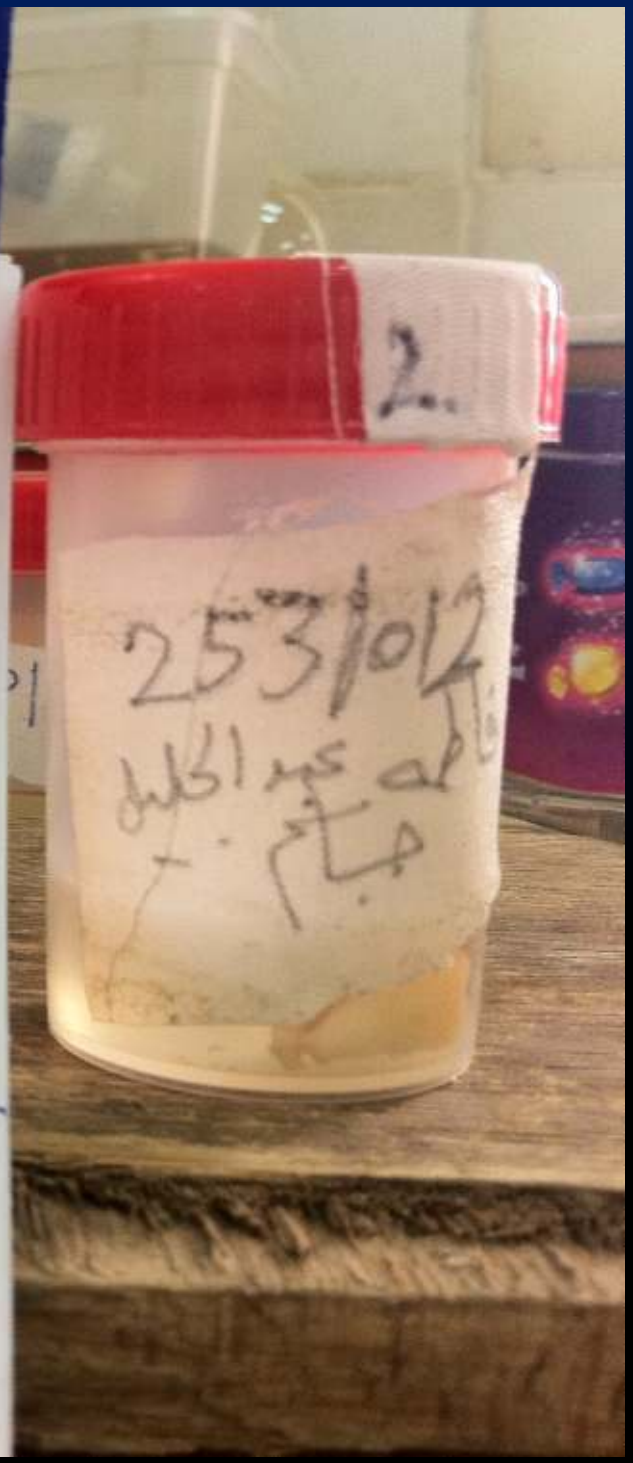

GCC
Xylol
Ethanol Absolute 2
Ethanol Absolute 1
90% Ethanol
70% Alcohol

Figure 2.1 Automatic tissue processor for processing by paraffin-embedding technique.
(Thermo Shandon, UK). Courtesy: Towa Optics (India) Pvt. Ltd., New Delhi.

063°

B
Control

MRS3500
Histo-Line
Laboratories

FISHER
TissuePrep™
Flotation Bath Model 135
HEAT
ON

Alcohol
100 %
Alcohol
90 %
Alcohol
80 %
Alcohol
80 %
Alcohol
90 %
Alcohol
100 %

Motic